

## Original Article

# The evaluation of malignant mucosal melanoma of nasal cavity with a rare occasion

Ahmet H Kepekci<sup>1</sup>, Cenk Kig<sup>2</sup>, Gul I Gundogan<sup>3</sup>

<sup>1</sup>Health Occupation High-School, Istanbul Yeni Yuzyil Universitesi, Istanbul, Turkey; Departments of <sup>2</sup>Medical Biology and Genetics, <sup>3</sup>Histology and Embryology, Faculty of Medicine, Istanbul Yeni Yuzyil Universitesi, Istanbul, Turkey

Received July 12, 2018; Accepted August 4, 2018; Epub August 10, 2018; Published August 20, 2018

**Abstract:** Malignant mucosal melanoma is an uncommon disease with a low rate of survival. Malignancies of nasal mucosa which usually presents with nasal obstruction, epistaxis and back drip are difficult to treat and often have poor prognosis. The present case had presented to our clinic with classic symptoms and diagnostic findings of nasal polyposis. Consistently, the patient had previously been diagnosed with and treated for nasal polyposis in another ENT clinic. Physical examination, rhinoscopic examination, computed tomography (CT) scan of the head did not reveal any findings which might imply malignant formations. The operation had been planned for nasal polypectomy and taking deep biopsy specimens. The incised mass showed characteristic features of malignant tissues and the pathology report of the biopsy samples revealed that the specimen showed the histological signs of malignancy. Based on physical examination, CT findings and pathology reports the case was diagnosed as nasal mucosal melanoma. Following an oncosurgical operation, postoperative radio-therapy and chemotherapy were given to the patient and PET/CT examination of the patient did not indicate distant metastases.

**Keywords:** Malignant mucosal melanoma, nasal polyposis, epistaxis, back drip, nasal obstruction

## Introduction

Mucosal melanomas in the head and neck region mainly occur in the upper respiratory tract, oral cavity, and pharynx. Additionally, mucosal melanomas can also originate from the mucosal membranes of the female genital organs or the anorectal and urinary tracts [1]. Mucosal melanoma of the head and neck represents approximately less than 1% of all the reported melanomas [2]. Due to the aggressive behaviour of mucosal melanomas, these tumors can metastasize to distant locations. The prognosis is generally not good with an estimated 5-year survival rate [3]. The incidence of mucosal melanoma of the head and neck region seems to increase by age (peaks 70 ( $\pm 10$ ) years of age) [1, 4].

Sinonasal mucosal melanoma has a very high potential for metastasis and the alternative treatment protocols are limited. Although mucosal melanoma shows resistance to radiation, some studies suggest a positive benefit. For instance, *in vitro* studies on cutaneous

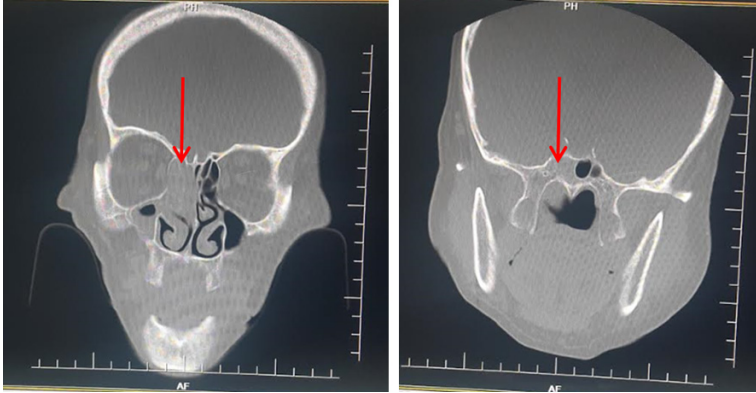
melanoma cell lines demonstrated that high dose radiation treatment might improve the outcome [5]. Owens et al. showed that post-operative radiotherapy was able to reduce the rate of local disease recurrence however, it did not significantly improve survival [6]. In this study, we will review the literature with a rare malignant mucosal melanoma of nasal cavity.

## Patient report

A 79-year-old female presented to our clinic with the complaint of nasal congestion (left side) and difficulty with breathing. The patient had been diagnosed with nasal polyposis in another clinic about 3 months earlier and was prescribed antihistamines and local cortisone spray. The patient stated that the treatment had initially improved her condition. However, the symptoms which started to appear 3 months ago seemed to get worse in time, and then she applied to our ENT clinic.

The patient did not have any other significant medical conditions or no pathologies had been

## Malignant mucosal melanoma of nasal cavity



**Figure 1.** Computed tomography of the head. A large mass blocking the air flow at the left nasal cavity is clearly visible (arrows), the mass was include the ethmoid cells.

made diagnosis surgical intervention for polypectomy and deep biopsy was considered as an option. Thus, the possibility for surgical intervention was discussed and agreed upon with the patient and her family. The patient did not have any systemic disorders therefore, only consultation for anesthesia was considered during preoperative assessment. The operation was planned for performing nasal polypectomy and taking deep biopsy specimens.



**Figure 2.** The appearance of the resected mass in the sample cup.

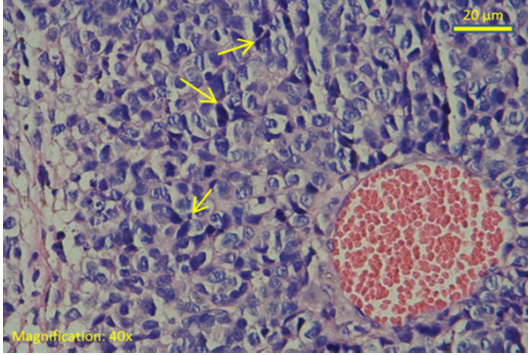
During the operation, the scope was inserted through the left nasal passageway under general anesthesia. Local anesthetic was sprayed on the nasal mass and resection of the mass was done using punch forceps. Upon visual examination, the mass was found to originate from the middle turbinate. It was necrotic and displayed the characteristic features of malignant tissues (**Figure 2**). The mass in the left nasal cavity was found to contain ethmoid cells. Subsequent to infiltration of anesthetic on the middle turbinate and the uncinata, uncinectomy was performed. Then, anterior and posterior etmoidectomy was performed and the operation was completed following insertion of merocel packings. No further interventions were carried out that could lead to permanent damage since histopathological diagnosis was not made. Post-operative complications had not been observed and therefore, adequate pain medications were prescribed and then the patient was discharged.

detected during the otoscopic examination. However, rhinoscopic examination revealed a large mass blocking the left nasal cavity and post nasal drip was noted. Computed tomography (CT) scan of the head, orbits, and sinuses revealed an opacification in the left frontal sinus, left sphenoid sinus and ethmoid cells which displayed the signs of loss of aeration. The left osteomeatal complex was obstructed and nasal septum was deviated towards the right side. Nasal conchae were normal, and no erosion or any other pathologies were detected within the bone structures which might indicate malignant formations (**Figure 1**).

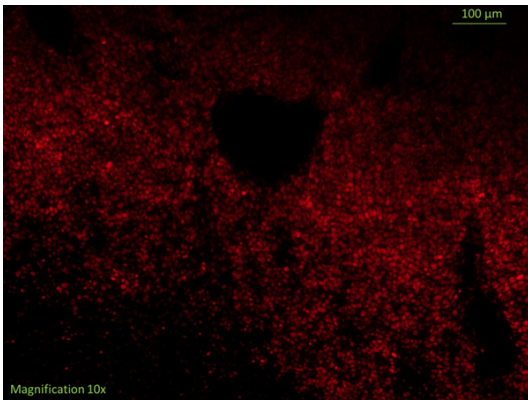
A piece of the tissue specimen (app. 3cc) was sent to a private laboratory for pathological analysis. Microscopic examination of the haematoxylin and eosin stained section, showed histological signs of malignancy. The nuclei were pleomorphic and hyperchromatic, and dark-colored pigmentation was detected. Tumor giant cells were also observed. Round and epithelioid cells with hyperchromatic nuclei were observed. A highly vascular connective tissue was also detected (**Figure 3**). Moreover, immunohistochemical analysis revealed that the sample was positive for the routinely used melanoma tumor markers S100 (**Figure 4**) and homatropin methylbromide HMB45 [13, 14].

Based on the findings from physical examination, analysis of CT scan and the previously

## Malignant mucosal melanoma of nasal cavity



**Figure 3.** Haematoxylin and eosin staining of the nasal tissue sample. (40× magnified image). Arrow pointed tumor giant cells.



**Figure 4.** Immunohistochemical staining of the nasal tissue sample for S100 (10× magnified image). The S-100 antibody was labeled with red fluorophore. The sample shows a wide spread malignant melanoma area stained positive for S-100.

Based on physical examination, CT findings and pathology reports the case was diagnosed as nasal mucosal melanoma. PET/CT examination of the patient did not indicate distant metastases. To decrease tumor load, a second operation was performed by oncosurgeons. Finally, postoperative radio-therapy and chemotherapy were given to the patient. PET/CT examination performed 2 months after oncosurgery did not reveal distant metastases.

### Discussion

Malignant melanoma of the sinuses usually presents with nasal obstruction, epistaxis and back drip. Unilateral nasal obstruction is amongst the most common symptoms of nasal melanomas in addition to nasal discharge, swelling, headache and deformity of the nose

[7]. Symptoms at later phases may include proptosis, diplopia, blurred vision, tearing [8]. The neoplasms of the paranasal sinuses can remain asymptomatic until they invade adjacent tissues, which are often located in close proximity to the vital structures such as the brain, orbits, and carotid artery [9]. Also, findings from a physical examination of the head and neck are important for diagnosis. For example, facial asymmetry, extraocular muscle dysfunction, defects in pupillary response, or eye globe displacement may imply nasal melanomas. Rhinoscopic examination, CT and MRI may be utilized for characterization of sinonasal malignancies prior to biopsy [10, 11].

Although, taking specimens for histological biopsy can trigger dissemination of tumour cells into circulation, biopsy remains the only reliable method for an accurate diagnosis of malignant melanomas [12]. Therefore, obtaining tissue samples by the least invasive method can be the most logical approach. In most cases, metastatic malignant melanomas are found to show positive staining with anti-S-100, HMB-45, and anti-vimentin [13]. Also, the presence of melanin is another hallmark of melanomas, which is thought to decrease the outcome of radiotherapy and increase the advancement of disease [14].

In this work, the patient who had previously been diagnosed with and treated for nasal polypsis in the other institution presented to our clinic with the complaint of nasal congestion on the left side. There were no signs of facial asymmetry, extraocular muscle dysfunction or globe displacement. Rhinoscopic examination of the patient revealed that the left nasal cavity was blocked by a large mass. Computed tomography (CT) scan of the head, showed that osteomeatal complex was obstructed. However, erosion or any other pathologies/deformities were not detected within the bone structures which might imply malignant formations (**Figure 1**).

This report displayed the classic symptoms and diagnostic findings of nasal polyposis. Thus, the operation had been planned for performing nasal polypectomy and taking deep biopsy specimens. When the mass had been removed it seemed to be necrotic and had characteristic features of malignant tissues (**Figure 2**). The pathology report of the biopsy samples revealed that the specimen showed the histological



signs of malignancy (**Figure 3**). The pathology report for the sample was positive for S100 (**Figure 4**) and HMB45 staining's which are among the markers commonly used for diagnosis of melanomas [13]. In a similar case, Alam M. et al., have presented a giant sinonasal mucosal melanoma case where a right sided nasal mass had been removed via surgical excision. The female patient presented with facial deformity and the diagnosis was made based on histopathological examination and immunohistochemistry [15].

Nasal mucosal malignant melanoma is known to have a high recurrence and metastasis rate. Recently, Kalogirou EM et al. reported an interesting case where a sinonasal mucosal melanoma has been found to recur 10 years after the initial diagnosis and treatment. This case suggests that, mucosal nasal melanoma has a long-term risk of *recurrence* and therefore patients should maintain lifelong follow-up [16]. In this view, it is also noteworthy to mention that PET/CT demonstrates a good accuracy in evaluation of patients with nasal mucosal melanoma. Especially, extended whole-body field of view enables PET/CT to detect distant metastatic formations. There, PET/CT is a valuable tool for assessment and long-term follow up of nasal mucosal melanoma patients [17].

### Acknowledgements

Written and signed consent from the patient has been obtained for publication of the case.

### Disclosure of conflict of interest

None.

**Address correspondence to:** Ahmet H Kepekci, Health Occupation High-School, Istanbul Yeni Yuzyil Universitesi, Meltem Hospital, Haznedar Mah., Ergene Sokađı No: 52, Güngören, İstanbul, Turkey. Tel: 00905332040462; E-mail: ahmethamdi.kepekci@yeniyuzyil.edu.tr

### References

- [1] Chai W, Gong F, Zhang W, Wen Y, Cui L. Multiple primary cancer in the female genital system: two rare case reports and a literature review. *Medicine* 2017; 96: e8860.
- [2] Lazarev S, Gupta V, Hu K, Harrison LB, Bakst R. Mucosal melanoma of the head and neck: a

- systematic review of the literature. *Int J Radiat Oncol Biol Phys* 2014; 90: 1108-1118.
- [3] López F, Rodrigo JP, Cardesa A, Triantafyllou A, Devaney KO, Mendenhall WM, Haigentz M Jr, Strojan P, Pellitteri PK, Bradford CR, Shaha AR, Hunt JL, de Bree R, Takes RP, Rinaldo A, Ferlito A. Update on primary head and neck mucosal melanoma. *Head Neck* 2016; 38: 147-155.
- [4] Tas F, Keskin S. Mucosal melanoma in the head and neck region: different clinical features and same outcome to cutaneous melanoma. *ISRN Dermatol* 2013; 2013: 586915.
- [5] Mohr P, Eggermont A, Hauschild A, Buzaid A. Staging of cutaneous melanoma. *Ann Oncol* 2009; 20: vi14-vi21.
- [6] Owens JM, Roberts DB, Myers JN. The role of postoperative adjuvant radiation therapy in the treatment of mucosal melanomas of the head and neck region. *Arch Otolaryngol Head Neck Surg* 2003; 129: 864-868.
- [7] Brandwein MS, Rothstein A, Lawson W, Bodian C, Urken ML. Sinonasal melanoma: a clinicopathologic study of 25 cases and literature meta-analysis. *Arch Otolaryngol Head Neck Surg* 1997; 123: 290-296.
- [8] Gasparyan A, Amiri F, Safdieh J, Reid V, Cirincione E, Shah D. Malignant mucosal melanoma of the paranasal sinuses: two case presentations. *World J Clin Oncol* 2011; 2: 344.
- [9] Alves I, Berriel L, Alves R, Pinto M, Oliveira C, Cazzotto A, Moura W. Sinonasal melanoma: a case report and literature review. *Case Rep Oncol Med* 2017; 2017: 8201301.
- [10] McLean N, Tighiouart M, Muller S. Primary mucosal melanoma of the head and neck. Comparison of clinical presentation and histopathologic features of oral and sinonasal melanoma. *Oral Oncol* 2008; 44: 1039-1046.
- [11] Mendenhall WM, Amdur RJ, Hinerman RW, Werning JW, Villaret DB, Mendenhall NP. Head and neck mucosal melanoma. *Am J Clin Oncol* 2005; 28: 626-630.
- [12] Kusakawa J, Suefuji Y, Ryu F, Noguchi R, Iwamoto O, Kameyama T. Dissemination of cancer cells into circulation occurs by incisional biopsy of oral squamous cell carcinoma. *J Oral Pathol Med* 2000; 29: 303-307.
- [13] Ben-Izhak O, Stark P, Levy R, Bergman R, Lichtig C. Epithelial markers in malignant melanoma. A study of primary lesions and their metastases. *Am J Dermatopathol* 1994; 16: 241-246.
- [14] Brożyna AA, Jóźwicki W, Roszkowski K, Filipiak J, Slominski AT. Melanin content in melanoma metastases affects the outcome of radiotherapy. *Oncotarget* 2016; 7: 17844-53.
- [15] Alam M, Aslam M, Singh PK, Hashmi SF, Hasan SA. Giant primary sinonasal mucosal melano-

## Malignant mucosal melanoma of nasal cavity

- ma: a rare malignancy. *Gulf J Oncolog* 2017; 1: 43-47.
- [16] Kalogirou EM, Kalyvas D, Tosios KI, Tsiklakis K, Sklavounou A. Recurrence in a patient with a 10-year history of sinonasal mucosal melanoma manifesting as facial swelling. *J Clin Exp Dent* 2017; 9: e1492.
- [17] Agrawal A, Pantvaiddya G, Murthy V, Prabhash K, Bal M, Purandare N, Shah S, Rangarajan V. Positron emission tomography in mucosal melanomas of head and neck: results from a South Asian tertiary cancer care center. *World J Nucl Med* 2017; 16: 197.